



**Vol. 5, Issue 4
inside this issue**

Varicose Veins: a Zoobiquitous Perspective..... Page 2
CVR Goes on the Speaking Trail, CVR Attends & Exhibits at ACP Congress, CVR TV Ads Aim to Educate Consumers, CMEs and Speaking Engagements..... Page 4

Superficial Venous Thrombophlebitis (SVT): To Refer or Not to Refer?



Update on New Practice Guidelines

by Arun Chowla, MD, FACS

Clinical Presentation

LM, a 78 year old female was seen in the emergency room with leg pain and localized swelling in the calf. Patient had no significant past medical history except for varicose veins. No history of prior leg clots or family history of clotting disorders. Physical exam showed a tender, reddened, indurated area over the lower thigh and medial calf. Patient was sent home with NSAIDS and supportive measures. Ultrasound of the left leg showed superficial thrombophlebitis involving the superficial calf veins and the great saphenous vein.

Ultrasound

Patient presented for further evaluation and her pain and redness had improved with mild

was stopped after the follow up.

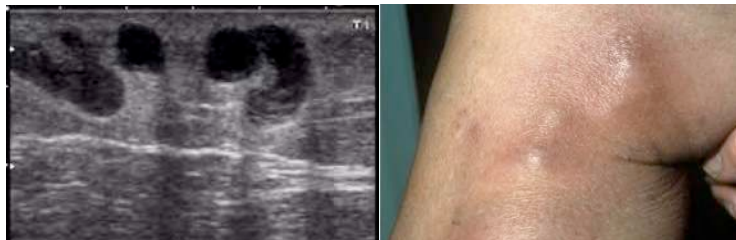Superficial Thrombophlebitis: Clinical Guidelines

Superficial Thrombophlebitis (SVT) refers to a clot in a superficial vein associated with surrounding inflammation. The usual clinical presentation is pain, tenderness, induration or erythema along a superficial vein. It is usually treated with NSAIDS (Ibuprofen, etc), compression stockings and warm compresses.

SVT is associated with varicose veins, malignancy, pregnancy, estrogen therapy, travel and history of prior leg clots.

Although SVT is less studied than deep venous thrombosis (DVT), it is seen more

commonly in the general population. Incidence of SVT is about 3-11%, compared to DVT which is about 1%. It may involve the great saphenous vein in 2/3 of the patients.



residual induration. Ultrasound in the office showed extension of great saphenous venous thrombus into the common femoral vein.

Treatment with Lovenox was started and continued on coumadin for 3 months. Follow up ultrasound in 3 months showed reflux in the great saphenous vein and resolution of the deep venous thrombosis. Patient underwent Radiofrequency Closure of the great saphenous vein as an outpatient procedure without complications. Coumadin

It is generally considered a benign, self limited disorder; but it may be complicated by extension of thrombus in the deep venous system. A recent prospective study of 844 patients with SVT > 5cm, 4% had symptomatic PE and ultrasound found proximal DVT in 10% and distal DVT in an exam was recommended in these patients with SVT above the knee.

The aim of treatment is not only to relieve

Continued on Page 3

VENOUS Review

Editorial Staff

Editor-in-Chief, President & CEO,
Center for Vein Restoration
Sanjiv Lakhanpal, MD, FACS

Editor
Robert C. Kiser, DO, MSPH

Associate Editor, Director of Research
& Director of Vascular Labs
Shekeeb Sufian, MD, FACS

Associate Editor, Director, Research &
Medical Education
Nicos Labropoulos, PhD, RVT

Managing Editor
Kathleen A. Hart

ISSN 2159-4767 (Print), ISSN 2159-4775 (Online)

Varicose Veins: a Zoobiquitous Perspective

by Robert C. Kiser, DO, MSPH

As animals, humans are classified as members of the Domain Eukaryota, kingdom Animalia, Phylum Chordata, class Mammalia, Order Primates, Family Hominidae, Genus Homo, and Species Homo sapiens. Physicians with degrees such as MD, DO, and DPM specialize in the diagnosis and treatment of humans. All other species are diagnosed and treated by physicians with designations such as Doctors of Veterinary Medicine. Traditionally there has been relatively little communication between human physicians and those who specialize in other species. The “zoobiquity” movement in medicine recognizes that ailments and diseases are ubiquitous across many animal species.¹

The zoobiquity movement has spearheaded the attempt to increase communication between physicians who tend to human patients and those that tend to other species. The purpose of zoobiquity is to allow important discoveries in all of animal and human science to be shared by all the medical and scientific disciplines involved in the care of any species. An excellent and interesting book on Zoobiquity is “Zoobiquity: What Animals Can Teach Us About Health and the Science of Healing” by cardiologist Barbara Natterson-Horowitz and Kathryn Bowers. The book gives many examples of how human and animal medical fields pursue parallel courses, and often can provide important information for each other.

Humans are unique among animals in their manifestation of chronic venous insufficiency of the lower extremities. This is largely because humans are bipedal, long-limbed and do not have the inelastic leg skin of birds. However, humans are not unique in getting varicose veins or at least distended and irregular veins; there are relatively few species that are known to be afflicted with them. Those that are do not manifest the same skin changes that humans experience.

Domesticated Animals

Domestic cows can often be seen to have varicose veins on their distended udders. In one of the closest analogies to human venous disease, a Pandharpuri buffalo (in India) was found to have a varicose sacral (tail) vein, leading to venous ulcer and signs such as hair loss of the tail and skin changes. In the case of the buffalo, however the cause was venous hypertension secondary to an arteriovenous fistula which is an unusual cause of varicose veins in humans.² Horses can get venous insufficiency and varicose veins of their legs, including enlarged leg veins known as “blood spavins.” Neither of these forms of enlarged vein routinely cause the type of skin changes or ulcerations that occur in humans with long-standing varicose veins. Horses also can manifest vulvar and vaginal varicosities, which can cause prolonged spontaneous bleeding.³

Wild Animals

In addition to animals that show similar disease patterns to humans, zoobiquity looks for animals that one would expect to have certain conditions but do not. Giraffes are evolutionarily and zoobiquitously interesting animals for several reasons. The giraffe’s extraordinarily long neck and height has required numerous adaptations as well as manifesting interesting vestigial anatomy that is peculiarly inefficient. The giraffe is often cited as an example of an animal exhibiting the tendency for a successful or selectively neutral design to remain in the gene pool despite its apparent inefficiency. In particular, the recurrent laryngeal nerve becomes tremendously inefficient in the giraffe; it originates as a branch of the vagus nerve and courses around thoracic arterial structures and then returns to the laryngeal area. This is a short and direct course in, say a fish where the analogous nerve takes a direct

path to the gills. In the giraffe it takes the same embryological-anatomical route, requiring a descent from the head, down the long neck and into the thoracic cavity where it does not connect, but rather wraps around arteries and then winds its way back up the to the larynx. This is the case with other vertebrates as well, but the length of the giraffe neck provides an extreme example of how evolution has kept this nerve in a working but extravagantly inefficient anatomical course.⁴

Similarly the length of the neck requires the arterial supply to the head to have several adaptations, including thick arterial walls to allow the blood pressure requirements for perfusion of the brain. The average arterial pressure for the giraffe is 185 ± 41.6 mmHg (systolic 211.1 ± 37.6 mmHg; diastolic 151.4 ± 32.6 mmHg).⁵ Certainly one would expect that giraffes, of all animals, would frequently develop venous insufficiency and varicose veins. However, this is not the case. The immunity of giraffes to varicose veins fascinated the inventor Frank Shaw, whose beloved wife Hertha suffered from intractable lymphedema. His discovery was that giraffes, despite having venous pressures of 250mmHg at their ankles, are immune from varicose veins because their skin is inelastic and their veins, being compressed by the tight and inelastic skin, cannot become distended. He used this observation to fashion the “Circ-Aid” device, which is a series of inelastic straps that wrap around the leg and provide relief from venous insufficiency and varicose veins while active and upright.⁶

Animal Models

Animal models for human disease can be essential for scientific hypothesis testing, although animal models of venous insufficiency have been very challenging to create. Most mammals being quadrupeds, attempts at creating increased venous pressure usually require the creation of an arterial-venous fistula. A canine model using greyhounds walking on their hind limbs allowed for measurement of increased venous pressures with upright posture, but no varicose veins or stasis changes were seen.⁷ A porcine model for venous hypertension that produces varicose veins has been created using a saphenous arterial-venous fistula. This approach has demonstrated the development of varicose veins of the hind limbs, with valve failure and macro and microscopic changes that are consistent with those found in humans. Due to the relative thickness of the pigs’ skin and the youth of the subjects at date, however, no stasis skin changes have been seen.⁸

Conclusion and Preview

Humans are fairly unique in the presentation of the cluster of signs and symptoms known as venous insufficiency, varicose veins and venous stasis skin changes. In next quarter’s newsletter, we will look at the evolutionary causes of the human predisposition to varicose veins.

Footnotes:

1. Natterson-Horowitz, B. “Zoobiquity: What Animals Can Teach Us About Health and the Science of Healing” Knopf, 2012.
2. White RA, Garing EL, Jackson PG, Noakes DE. Persistent vaginal haemorrhage in five mares caused by varicose veins of the vaginal wall. *Vet Rec.* 1984 Sep 15;115(11):263-4.
3. Buffalo Bulletin Vol.24 No.2 (June 2005) p. 24
4. Dawkins, R. *The Greatest Show on Earth: The Evidence for Evolution.* Free Press; Reprint edition (August 24, 2010).
5. Mitchell, G. and Skinner, J. D. (1993). How giraffe adapt to their extraordinary shape. *Trans. R. Soc. S. Afr.* 48,207 -218.
6. http://www.circaid.com/news/pr/2011/09152011_HerthaStory.php
7. Dalsing MC, Zukowski AJ, Unthank JL, Lalka SG, Sawchuk AP, Cikrit DF. Details of a canine venous insufficiency model. *J Invest Surg.* 1994 Mar-Apr;7(2):85-93.
8. *Medicographia* Vol 30, No.2, 2008 A journal of medical information and international communication from Servier, Issue 95, pages 154-156.



Superficial Venous Thrombophlebitis (SVT): To Refer or Not to Refer? Update on New Practice Guidelines

Continued from Page 1

local symptoms but also to prevent thromboembolic complications. But the role of anticoagulation is controversial. Most studies have been small and have shown benefit over placebo, but the evidence was of low quality. The CALISTO Study (Comparison of Arixtra in Lower Limb Superficial Thrombophlebitis with Placebo) was recently published which showed benefit of Fondaparinux (Arixtra 2.5mg/d for 45 days) over placebo in 3,000 patients with lower limb SVT > 5cm, with lowered incidence of venous thromboembolism, recurrent SVT, and extension of SVT.

Based on these studies, the American College of Chest Physicians have also issued new guidelines in February 2012 and have recommended anticoagulation for patients with SVT who are at increased risk for venous thromboembolism (SVT > 5cm, proximity to deep veins < 5cm, positive medical risk factors). Positive medical risk factors include prior clots, cancer, surgery, thrombophilia, estrogen therapy or prolonged travel. Fondaparinux 2.5mg daily or enoxaparin 40 mg daily for a period of 4 weeks is recommended. If DVT is present, patient should be fully anticoagulated.

Ligation of great or small saphenous vein may be considered in patients in whom anticoagulation is contraindicated. Otherwise surgery for SVT was found to be associated with a higher risk for thromboembolism.

Patient with isolated SVT and no associated risk factors may be diagnosed by physical exam and treated with NSAIDs, compression stockings and ambulation. Repeat physical exam should be done in 7-10 days to evaluate for extension or resolution.

Duplex Ultrasound should be done in patients with SVT > 5cm, involvement of GSV or SSV, presence of phlebitis above the knee, or extension of phlebitis on serial exam.

In summary, new data from recent studies and guidelines from ACCP have clarified the role of anticoagulation in SVT. SVT should not be regarded as a benign disorder and further evaluation and anticoagulation should be considered in patients high risk for thromboembolism. SVT may also be a marker for thrombophilia or other conditions like malignancy and therefore recurrent SVT should prompt further detailed assessment and evaluation.

References:

- Decousus H, Quéré I, Presles E, et al. Superficial venous thrombosis and venous thromboembolism: a large, prospective epidemiologic study. *Ann Intern Med* 2010; 152:218.
- Di Nisio M, Wichers IM, Middeldorp S. Treatment for superficial thrombophlebitis of the leg. *Cochrane Database Syst Rev* 2007; :CD004982.
- Decousus H, Prandoni P, Mismetti P, et al. Fondaparinux for the treatment of superficial-vein thrombosis in the legs. *N Engl J Med* 2010; 363:1222.
- Kearon C, Akl EA, Comerota AJ, et al. Antithrombotic therapy for VTE disease: Antithrombotic Therapy and Prevention of Thrombosis, 9th ed: American College of Chest Physicians Evidence-Based Clinical Practice Guidelines. *Chest* 2012; 141:e419S.

CVR Expands to New York

Center for Vein Restoration is excited to announce we're expanding to the New York market; we'll soon be opening our first clinic in Westchester County, NY. Helping us lead this expansion is our newest team member, Gautum V. Shrikhande, MD. Dr. Shrikhande is a talented, vascular surgeon and Assistant Professor of Surgery and Director of the Vascular Laboratory, Columbia University Medical Center. He is Board Certified in General and Vascular Surgery and is a Registered Physician in Vascular Interpretation (RPVI). He recently joined Center for Vein Restoration – the largest physician-led vein treatment practice in the country -- to lead its expansion into the New York market; CVR already serves patients in more than 20 clinical locations in the Mid Atlantic and East Coast, with corporate headquarters near Washington D.C.

While a skilled clinician, Dr. Shrikhande also is known as a talented researcher and prolific writer. His published papers have appeared in many top medical



journals, including the Journal of Vascular Surgery, the World Journal of Surgery, Blood, Hepatology, Vascular and Endovascular Surgery and the Journal of Endovascular Therapy. He also recently co-edited a book – Diabetes and Peripheral Vascular Disease: Diagnosis and Management (Humana Press) – a guide for physicians, which is available on Amazon.com (<http://tinyurl.com/c89zsku>). He also is in the process of patenting a specialized filter to be used in vascular surgery.

Dr. Shrikhande studied at Trinity College in Hartford, Conn., and earned his MD at the University of Connecticut Medical School. He later trained in general surgery at Beth Israel Deaconess Medical Center, Harvard Medical School. He completed his vascular surgery fellowship at New York Presbyterian, the University Hospitals of Cornell and Columbia. He resides in the Carnegie Hill neighborhood of Manhattan with his wife, Dr. Allyson Shrikhande, and their daughter, and is a member of the Guggenheim.



Q: "If I am sending a patient to you who has an ulcer, should I also send him or her to a wound center as well?"

A: No, foot ulcers can have various etiologies, several of which have to do with the circulatory system in general, such as - arterial insufficiency, diabetes, venous insufficiency and/or a combination of any or all of the above. At Center for Vein Restoration, we can evaluate the patient and his

or her specific wound at any of our centers. Those ulcers that are from a source such as diabetes and/or arterial insufficiency can be cared for at our sister practice "The Center for Vascular Medicine," which specializes in these types of patient care issues. Wounds that are from a venous etiology can be cared for and definitively treated at a CVR office.

Q: "If you ablate one vein will it cause reflux to occur in another?"

A: No, although many patients may have multiple areas of venous reflux involving multiple veins, once a single vein is treated the efficacy of that treatment is over 95%. In other words, once a vein is ablated, that vein will stay closed permanently. Ablation is a very durable solution. Other veins, may, however require additional treatments including ablation or other therapeutic modalities such as sclerotherapy or phlebectomy depending on the size and location of the offending veins.

- John Pietropaoli, M.D., F.A.C.S.



CVR Goes on the Speaking Trail

Center for Vein Restoration physicians were proud to address a pair of recent medical groups:

■ CVR sponsored the Asian American Medical Society meeting on October 18, 2012 in Arlington, VA. Our doctors Khan Nguyen, DO, Richard Nguyen, MD, Arun Chowla, MD and Sean Stewart, MS, MD led a discussion on venous insufficiency and presented a check to the organization for \$3,500 to help support world health in East Asian countries.



■ Our physicians also were pleased to present at the Oct. 27 Washington D.C. Dermatological Society's Clinical Conference at Inova Fairfax Hospital.

About 70 dermatologists attended the event, which included our participation in a Live Case presentation and discussing management of Inferior Vena Cava Occlusion in a patient with thrombophilia and leg ulceration. The presentation given by CVR's Dr. Arun Chowla, also included a live ultrasound demonstration by our expert Vascular Tech Melissa Muto and an overview of CVR by our Director of Growth and Development Bob Howell. CVR was a sponsor of the conference.

CVR Attends, Exhibits at ACP Congress

Center for Vein Restoration was out in force at the Nov. 15-18 American College of Phlebology Annual Congress in Hollywood, Florida. Our physicians attended several educational sessions,



while we also for the first time exhibited, giving us more opportunity to meet colleagues from around the country.

Among the things we discussed were CVR's expansion plans and our continuing need to recruit talented physicians, vascular technicians, nurses, surgical assistants and management professionals.

New CME Announced

We are pleased to announce more CME sessions for winter 2013 on venous insufficiency. Each course is valued at 3 CME credits. Details are below; to learn more or to request a CME in a region we serve, please contact Brent Matherly at 443-370-3830 or 301-860-0930 and at brent.matherly@centerforvein.com.

CME COURSES & SPEAKING ENGAGEMENTS

JANUARY

VIRGINIA

Reston
Thursday, January 24
Paolo's Restaurant
11898 Market Street
Reston, VA 20190

RSVP by January 16
Beth Graff, Physician Liaison
at (412) 952-6557 or
beth.graff@centerforvein.com

**WOULD YOU LIKE US TO OFFER A CME COURSE NEAR YOU?
PLEASE CONTACT BRENT MATHERLY
AT 443-370-3830 OR 301-860-0930 AND AT BRENT.MATHERLY@CENTERFORVEIN.COM**


CVR TV Ads Aim to Educate Consumers

Have you seen us on TV? As part of our commitment to educate the public about venous disease and treatment options, we've launched a series of TV ads in the Washington-Baltimore region. The spots were created with the help of agency DMW Direct.

One ad gives examples of complaints we've received from real patients to highlight the symptoms and the personal cost of varicose veins: "My legs hurt all the time," "I'm tired of leg cramps that keep me up all night," "I'm embarrassed to wear shorts," "I don't like hospitals," and so on. To illustrate the problem, the text of the complaints forms what looks like varicose veins on a patient's leg. Then, a voiceover cautions the audience not to let symptoms linger and offers free consultations.

The second ad features a CVR Patient Services consultant taking calls from the public, again highlighting common questions we receive, detailing symptoms and offering free screenings.

You can view the ads on our Web site or on YouTube or Facebook; just search under "Center for Vein Restoration."



OUR PHYSICIANS & LOCATIONS



1. Sanjiv Lakhnpal, M.D., F.A.C.S.
2. Jaime Marquez, M.D., F.A.C.S.
3. Shekeeb Sufian, M.D., F.A.C.S.
4. Luis A. Dibos, M.D., F.A.C.S.
5. Thomas Militano, M.D., F.A.C.S.
6. Frank Sbrocco, M.D.
7. Arvind Narasimhan, M.D.
8. Khanh Nguyen, D.O.
9. Eddie Fernandez, M.D.
10. J. Andrew Skiendzielewski, D.O.
11. Stéphane Corriveau, M.D.
12. Rory C. Byrne, M.D.
13. Rob Kiser, D.O.
14. John Pietropaoli, M.D., F.A.C.S.
15. Sean K. Stewart, M.D.
16. Richard Nguyen, MD
17. Khoa Tran, MD
18. Arun Chowla, MD, F.A.C.S.
19. Vinay Satwah, DO, FACOI
20. Gautam Shrikhande, MD

Administrative Offices Maryland Trade Center 2, 7474 Greenway Center Drive, Suite 1000, Greenbelt, MD 20770 Ph: (240) 965-3200

Maryland

Annapolis

108 Forbes Street
Annapolis, MD 21401
Ph: (410) 266-3820

Baltimore/Towson

7300 York Road, Suite LL
Towson, MD 21204
Ph: (410) 296-4876

Bel Air

2225 Old Emmerton Rd., Suite 110
Bel Air, MD 21015
Ph: (410) 569-3604

Columbia

Medical Arts Building
11085 Little Patuxent Parkway, Suite 203
Columbia, MD 21044
Ph: (410) 730-2784

Easton

505A Dutchman's Lane, Suite A-2
Easton, MD 21601
Ph: (410) 770-9401

Germantown

19785 Crystal Rock Dr., Suite 310
Germantown, MD 20874
Ph: (301) 515-7203

Glen Burnie

1600 Crain Highway, Suite 408
Glen Burnie, MD 21061
Ph: (410) 424-2237

Greenbelt

7300 Hanover Drive, Suite 303
Greenbelt, MD 20770
Ph: (301) 441-8807

Prince Frederick

301 Steeple Chase Drive, Suite 401
Prince Frederick, MD 20678
Ph: (410) 414-6080

Rockville

11119 Rockville Pike, Suite 101
Rockville, MD 20852
Ph: (301) 468-5781

Takoma Park/Silver Spring

831 University Blvd. East, Suite 24-25
Silver Spring, MD 20903
Ph: (301) 891-6040

Waldorf

12107 Old Line Center
Waldorf, MD 20602
Ph: (301) 374-2047

District of Columbia

Washington #1

106 Irving Street, N.W., Suite 2400 N
Washington, DC 20010
Ph: (202) 722-0603

Washington #2

3301 New Mexico Ave. NW., Suite 336
Washington, DC 20010
Ph: (301) 860-0930

Virginia

Alexandria

1900 N. Beauregard Street, Suite 110
Alexandria, VA 22311
Ph: (703) 379-0305

Fairfax/Fair Oaks

3620 Joseph Siewick Dr.
Suite 303
Fairfax, VA 22033
Ph: (703) 650-9712

Fairfax/Merrifield

8316 Arlington Boulevard, Suite 514-A
Fairfax, VA 22031
Ph: (703) 289-1122

Leesburg

44035 Riverside Parkway, Suite 400
Leesburg, VA 20176
Ph: (800) 349-5347

Woodbridge

2200 Opitz Blvd, Suite 320
Woodbridge, VA 22191
Ph: (703) 490-8585

Michigan

Kalamazoo/Portage

3810 West Centre Avenue, Suite A
Portage, MI 49024
Ph: (269) 323-8000



Editor-in-Chief, President & CEO,
Center for Vein Restoration
Sanjiv Lakhanpal, MD, FACS



Editor,
Robert C. Kiser, DO, MSPH

This is a magical time of year. Holidays are top of mind, as are the celebrations that go along with them. But for many of our patients, the parties, travel and visits with friends and family can be a burden. With poor vein health they struggle to keep up due to a range of symptoms, from discomfort and heavy legs to reduced mobility and pain. Some may also just be too embarrassed by their appearance to join in the holiday spirit – let alone pose for pictures with relatives.

We are reminded each year at this time that we are blessed with the extraordinary task of helping our patients simply to return to being ordinary. They want to look better, feel better and live better, and we're privileged to be able to assist them in that effort.

As we look back on 2012 and ahead to 2013 we're proud of many things, not the least of which is providing service to more patients than ever. We recently opened our 20th clinic and we'll have news soon about exciting new markets. We also have been proud to continue our research into vein health and to share our knowledge with local physicians through our robust CME program. We're proud to sponsor, exhibit and speak at a growing number of regional and national medical conferences, and we've even begun educating consumers through an informative new TV ad campaign.

We thank you for your continued interest in Center for Vein Restoration. As always, we hope you find our newsletter helpful and we wish you and yours a happy and healthy holiday season and prosperous New Year.

Yours in good health,

Robert C. Kiser, DO, MSPH

Editor

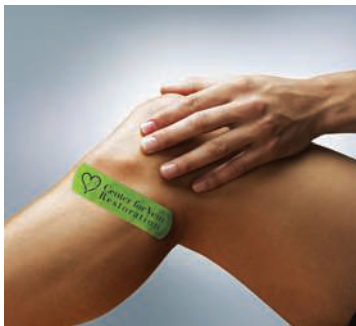

Visit our website: www.centerforvein.com



Center for Vein Restoration

Maryland Trade Center 2
7474 Greenway Center Drive
Suite 1000
Greenbelt, MD 20770



**SOON...
BRINGING
RELIEF TO
WESTCHESTER
COUNTY**